

Ultrasound Imaging Module: Report from the GRAPPA 2012 Annual Meeting

Gurjit S. Kaeley

ABSTRACT. At previous annual meetings of the Group for Research and Assessment of Psoriasis and Psoriatic Arthritis (GRAPPA), members resolved to develop dactylitis and enthesitis ultrasound research projects. Sonography can depict many anatomic alterations in the digits of patients with dactylitis and can also study vascularity of these tissues noninvasively. At the 2012 GRAPPA meeting, the ultrasound workgroup outlined steps in developing a dactylitis outcome measure: determining sonographic elemental lesions; testing to see which of these are the most discriminant in separating dactylitic digits from normal digits; selecting final elements for a sonographic dactylitis index; and conducting validity and reliability testing. A brief update of the enthesitis project was also presented. (J Rheumatol 2013;40:1450–2; doi:10.3899/jrheum.130461)

Key Indexing Terms:

PSORIATIC ARTHRITIS SONOGRAPHY DOPPLER ENTHESITIS DACTYLITIS

Sonography is a high-resolution non-ionizing imaging modality that can be applied to study the musculoskeletal manifestations of psoriatic arthritis (PsA). At the 2012 annual meeting of the Group for Research and Assessment of Psoriasis and Psoriatic Arthritis (GRAPPA), members resolved to develop a GRAPPA dactylitis and enthesitis ultrasound research program. At the 2012 meeting in Stockholm, Sweden, progress on developing these programs was reported.

Dactylitis or sausage-shaped digit is a pathognomonic sign of spondyloarthropathies. It can present as a painful digit or as a relatively asymptomatic chronically swollen digit. It occurs in 16%–48% of subjects with PsA^{1,2}, and may be defined clinically as uniform diffuse swelling of the soft tissues of a digit such that actual joint swelling could no longer be independently recognized³. It may be the sole manifestation of PsA² and may be associated with erosive joint disease⁴. Its importance as a key feature in PsA is underscored by the fact that it is one of the elements of the CIASSification for Psoriatic ARthritis (CASPAR) criteria. Due to the paucity of clinical instruments measuring dactylitis, the Leeds Dactylitis Index was developed to measure swelling or tenderness⁵. However, this tool cannot accurately specify tissue compartments that contribute to the digital swelling.

The concept of involvement of multiple tissue compartments in PsA dactylitis has evolved over time. Early

imaging studies suggested that the appearance of dactylitis was predominantly due to flexor tenosynovitis^{6,7,8}. Kane, *et al* also documented presence of small joint synovitis in dactylitic digits. Involvement of soft tissues was initially demonstrated by Jevtic, *et al*, who reported diffuse soft tissue edema as well as collateral ligament involvement in addition to interphalangeal joint synovitis on Gd-DTPA contrast-enhanced magnetic resonance imaging (MRI) in 2 PsA patients with dactylitis⁹. Fournié, *et al* further demonstrated soft tissue thickening in PsA patients with dactylitis, which they characterized as pseudotenosynovitis¹⁰. The diffuse involvement of soft tissues in addition to flexor tenosynovitis in digits was further confirmed by MRI studies by Healy, *et al*¹¹ and Olivieri, *et al*¹². Healy, *et al* also reported concurrent joint synovitis, collateral ligament involvement, and palmar plate involvement in a proportion of dactylitic digits.

At present, extensive studies have not been done of the natural history and detailed longitudinal changes of soft tissue changes in dactylitis. In designing imaging measures for dactylitis, consideration should be given to evaluating the various ultrastructural changes. Thus, the measures should include not only quantitative measures of soft tissue thickening, flexor tendon thickening and tenosynovitis, and extensor tendon thickening, but also assessment of joint pathology, osseous changes, and intra- and extraarticular erosions. As noted, mounting evidence shows that dactylitis may be caused by inflammation of multiple structures in the fingers and not just by flexor tenosynovitis and synovitis. All these changes, except for bone marrow edema, can be examined with high resolution ultrasonography. However, sonography offers excellent resolution to study bone formation and erosions as well as alterations in the various compartments of the finger. The additional advantage of sonography is the utilization of power Doppler to infer areas of active inflammation.

From the Division of Rheumatology, University of Florida College of Medicine, Jacksonville, Florida, USA.

G.S. Kaeley, MBBS, MRCP, Division Chief, Associate Professor of Medicine and Program Director, Director of Musculoskeletal Ultrasound, Division of Rheumatology, University of Florida College of Medicine.

Address correspondence to Dr. G.S. Kaeley, Division of Rheumatology, University of Florida College of Medicine, 653-1 West Eight Street, LRC 2nd Floor L-14, Jacksonville, FL 32209-6561, USA.
E-mail: drgurj@gmail.com

GRAPPA dactylitis ultrasound project

The GRAPPA dactylitis ultrasound project is being developed in collaboration with the OMERACT (Outcome Measures in Rheumatology) ultrasound group. The proposed methodology was presented at the GRAPPA 2012 meeting. The goal of this project is to produce a sonographic dactylitis outcome measure that is reliable, feasible, and discriminant. The first step of the process is to identify elements that may differentiate dactylitic digits from normal digits. Candidate elemental lesions were preliminarily identified after a systematic literature review and are listed in Table 1¹³.

Investigators will be asked to submit candidate sonographic images of dactylitis with justification. Data from the literature review and image submission will then be used in a Delphi process to finalize candidate elemental lesions, and these elements will be tested to determine which can discriminate dactylitic digits from normal digits. A prediction model to separate dactylitic digits from normal digits will be developed by conducting a multicenter cross-sectional study. The results from that study will allow construction of a sonographic dactylitis index, which may then undergo reliability testing (Figure 1).

GRAPPA enthesitis ultrasound project

The rationale for developing a sonographic enthesitis index specific for PsA was discussed at the 2010 and 2011 GRAPPA annual meetings^{14,15}. At the 2012 meeting, Dr. Kaeley reported that a protocol is under development. Sonographic examination of perientheseal tissues was also outlined.

Discussion

GRAPPA members discussed development of a composite sonographic measure of PsA that would include joints, skin,

and entheses as well as nails. It was felt that validation of individual domains was needed prior to development of a global scoring system. The potential role of sonography in evaluating skin thickness and vascularity was discussed. Members suggested that ultrastructural changes such as alterations in epidermal rete ridges should also be sought with high resolution sonography.

Previous reports of cross-sectional studies revealing subclinical enthesitis in psoriasis patients led to discussion of a future longitudinal study to examine the natural history of subclinical enthesitis in patients with psoriasis.

The role of GRAPPA in fostering use of sonography for PsA as well as standardization of scanning protocols for PsA was discussed. Participants discussed differences in scanning equipment, how a validation process may aid in standardizing minimal requirements, and the reliability and validity of the sonographer. Participants agreed that both acquisition and reading of images must be reliable, which may be enabled by developing standardized scanning protocols and promoting reliability exercises especially for sonographic multicenter studies. Use of the GRAPPA website for training materials was suggested.

In summary, ultrasonography is a promising tool that can examine many cutaneous and skeletal manifestations of psoriasis and PsA. The GRAPPA ultrasound workgroup will continue to develop sonographic outcome measures in dactylitis and enthesitis and will begin investigating use of ultrasound to study arthritis in patients with PsA. This latter project may include longitudinal studies to predict progression of joint damage as well as osteoproliferation and possible concurrent study of soluble biomarkers.

ACKNOWLEDGMENT

I am grateful to Maria Antoinetta D'Agostino and Ignazio Olivieri in

Table 1. Candidate dactylitis sonographic lesions.

Lesion	Comments
I. Synovitis	OMERACT definition: synovial hypertrophy with or without Doppler signal ¹⁶
II. Tenosynovitis	OMERACT definition: hypoechoic or anechoic material within synovial sheath, with or without fluid, seen in 2 perpendicular planes and which may exhibit Doppler signal ¹⁶
III. Superficial edema	Defined by anechoic areas superficial to the tendon within the subcutaneous tissues Presence or absence will be recorded
IV. Soft tissue thickening	Measurements of soft tissue thickness on dorsal and volar aspects
V. Osteoproliferation	Presence or absence of bony irregularities/osteophytes
VI. Intracapsular joint calcification	Presence or absence of intracapsular calcification
VII. Profundus enthesitis	Presence or absence of abnormalities of profundus insertion, vascularity
VIII. Collateral ligament thickening	Presence or absence of thickening, vascularity
IX. Nail abnormalities	Nail plate: presence or absence of bilayer obliteration Nail bed: measurement of mid-bed thickness Nail bed vascularity: semiquantitative scoring; by Doppler signal

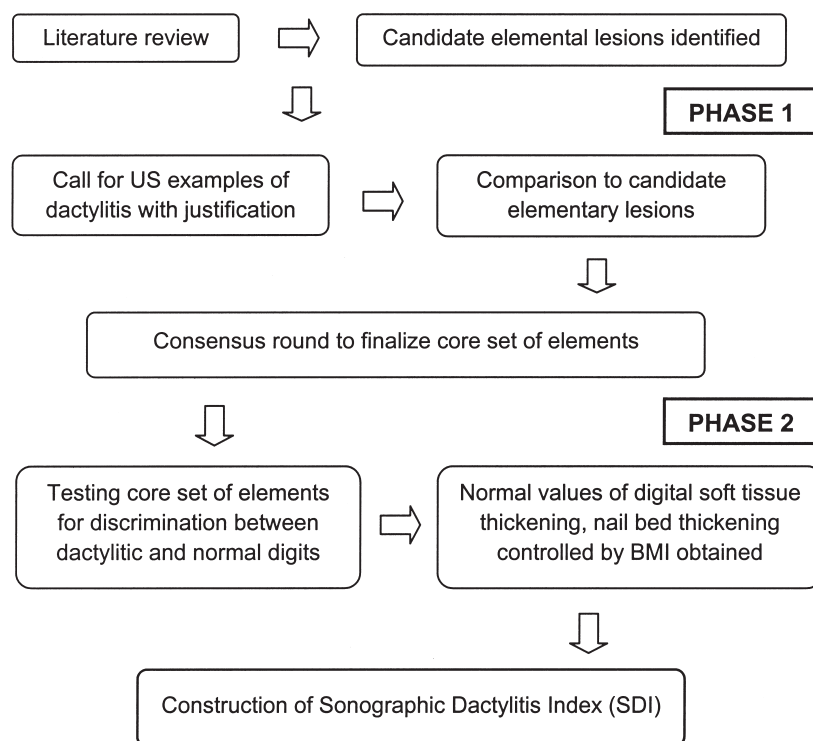


Figure 1. Proposed methodology in development of sonographic dactylitis outcome measure. US: ultrasound; BMI: body mass index.

assisting with the dactylitis and enthesitis program development, and to Phillip Helliwell and Dafna Gladman for their critical protocol review and suggestions.

REFERENCES

- Olivieri I, Padula A, Scarano E, Scarpa R. Dactylitis or "sausage-shaped" digit. *J Rheumatol* 2007;34:1217-22.
- Taylor W, Gladman D, Helliwell P, Marchesoni A, Mease P, Mielants H. Classification criteria for psoriatic arthritis: Development of new criteria from a large international study. *Arthritis Rheum* 2006;54:2665-73.
- Rothschild BM, Pingitore C, Eaton M. Dactylitis: implications for clinical practice. *Semin Arthritis Rheum* 1998;28:41-7.
- Brockbank JE, Stein M, Schentag CT, Gladman DD. Dactylitis in psoriatic arthritis: A marker for disease severity? *Ann Rheum Dis* 2005;64:188-90.
- Helliwell PS, Firth J, Ibrahim GH, Melsom RD, Shah I, Turner DE. Development of an assessment tool for dactylitis in patients with psoriatic arthritis. *J Rheumatol* 2005;32:1745-50.
- Olivieri I, Barozzi L, Favaro L, Piero A, de Matteis M, Borghi C, et al. Dactylitis in patients with seronegative spondylarthropathy. Assessment by ultrasonography and magnetic resonance imaging. *Arthritis Rheum* 1996;39:1524-8.
- Kane D, Greaney T, Bresnihan B, Gibney R, FitzGerald O. Ultrasonography in the diagnosis and management of psoriatic dactylitis. *J Rheumatol* 1999;26:1746-51.
- Wakefield RJ, Emery P, Veale D. Ultrasonography and psoriatic arthritis. *J Rheumatol* 2000;27:1564-5.
- Jevtic V, Watt I, Rozman B, Kos-Golja M, Demsar F, Jarh O. Distinctive radiological features of small hand joints in rheumatoid arthritis and seronegative spondyloarthritis demonstrated by contrast-enhanced (Gd-DTPA) magnetic resonance imaging. *Skeletal Radiol* 1995;24:351-5.
- Fournie B, Margarit-Coll N, Champetier de Ribes TL, Zabraniecki L, Jouan A, Vincent V, et al. Extrasynovial ultrasound abnormalities in the psoriatic finger. Prospective comparative power-doppler study versus rheumatoid arthritis. *Joint Bone Spine* 2006;73:527-31.
- Healy PJ, Groves C, Chandramohan M, Helliwell PS. MRI changes in psoriatic dactylitis — extent of pathology, relationship to tenderness and correlation with clinical indices. *Rheumatology* 2008;47:92-5.
- Olivieri I, Scarano E, Padula A, D'Angelo S, Salvarani C, Cantini F, et al. Fast spin echo-T2-weighted sequences with fat saturation in toe dactylitis of spondyloarthritis. *Clin Rheumatol* 2008;27:1141-5.
- Kaeley GS. Review of the use of ultrasound for the diagnosis and monitoring of enthesitis in psoriatic arthritis. *Curr Rheumatol Rep* 2011;13:338-45.
- Kaeley GS, Bakewell CJ. The ultrasound imaging module: A report from the GRAPPA 2010 annual meeting. *J Rheumatol* 2012;39:404-7.
- Kaeley GS, D'Agostino MA, Grassi W, Ostergaard M, Olivieri I. GRAPPA 2011: Proceedings from the ultrasound imaging module. *J Rheumatol* 2012;39:2211-3.
- Wakefield RJ, Balint PV, Szkudlarek M, Filippucci E, Backhaus M, D'Agostino MA, et al. Musculoskeletal ultrasound including definitions for ultrasonographic pathology. *J Rheumatol* 2005;32:2485-7.